

# MODIFICATION OF A CONVENTIONAL DENTURE FOR USE AS AN IMPLANT-RETAINED AND -STABILIZED OVERDENTURE:



Figure 1.

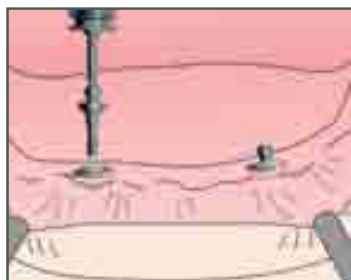


Figure 2.

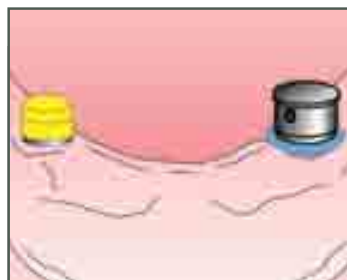


Figure 3.

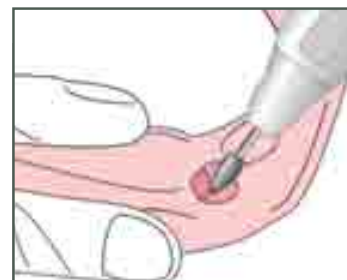

Figure 4.

## Introduction

In 2002, a group of distinguished scientists and clinicians met at McGill University in Montreal, Quebec, to discuss evidence-based restorative options for the edentulous mandibular arch.<sup>1</sup> After reviewing data from randomized clinical trials and epidemiological studies, the panel issued a landmark consensus statement identifying the mandibular overdenture stabilized by two implants as the first-choice standard of care for edentulous mandibles.<sup>1-2</sup> Data presented at the symposium<sup>1</sup> and by numerous subsequent studies<sup>2</sup> have documented the ease of implementation and significant improvements in patient comfort, satisfaction and prosthesis stability provided by implant-stabilized overdentures compared to conventional dentures.

This article will briefly review the underlying principles and techniques for stabilizing an overdenture with two AdVent® dental implants with Ball Abutments and Cap Attachments (Zimmer Dental Inc., Carlsbad, CA, USA).

**Figure 1.** Restorative components include the implant, Ball Abutment and Cap Attachment assembly.

**Figure 2.** Ball Abutments are threaded into the implants and torqued to 30 Ncm.

**Figure 3.** A Cap Attachment Transfer (left) and Housing (right) are placed onto each Ball Abutment and undercuts are blocked out with soft material.

**Figure 4.** Voids created in the denture base allow Cap Attachment Housings to fit passively inside. Small lingual vents are also created through the denture base.

**Figure 5.** Autopolymerizing acrylic placed in each void adheres to the Housings when the denture is placed into the patient's mouth. Excess acrylic will express through the lingual vent.

**Figure 6.** Cap Attachment Housings picked up in the denture base.

**Figure 7.** A retentive Cap Attachment Nylon Liner is placed into one housing at a time and evaluated intraorally for retention strength.

**Figure 8.** The completed restoration can be removed by the patient for oral hygiene.

## DESIGN CONCEPT & DIRECT PICK-UP TECHNIQUE

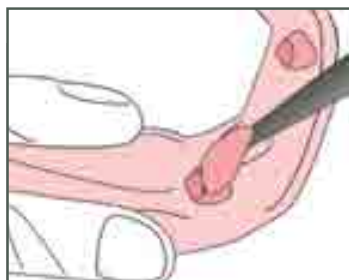

Figure 5.

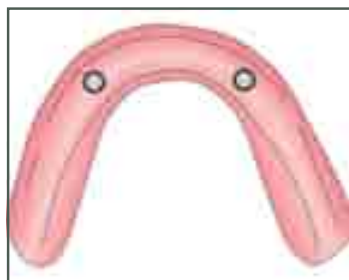

Figure 6.

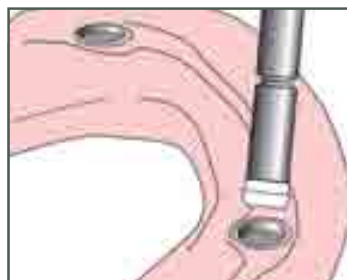

Figure 7.

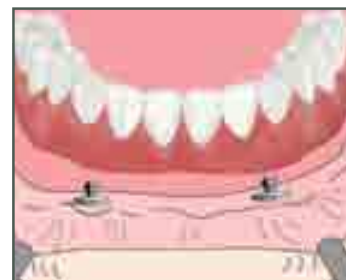

Figure 8.

### Design concept

One implant is placed in the mandibular symphysis region on each side of the midline and restored with a Ball Abutment. Retentive Cap Attachments are processed into the overdenture base and snap onto the Ball Abutments to retain and stabilize the overdenture [Fig. 1]. The underlying restorative goal is to maintain complete soft-tissue support of the prosthesis by allowing the overdenture to rotate freely on the resilient attachments. Placing more than two implants with similar attachments reduces or eliminates the rotational movements of the overdenture on the Ball Abutments and may transfer undesirable fulcrum-type stresses to the implants themselves. This could result in implant overloading. If left untreated, implant overload can cause progressive peri-implant bone loss and eventual component fracture.

Each retentive Cap Attachment provides five pounds of retention when snapped onto the Ball Abutment. This retention can also be decreased to meet the needs of individual patients. Absolute parallelism of the Ball Abutments is not necessary because the Cap Attachments can be attached to their respective Ball Abutments, then rotated to create a common path of draw with one another

Requirements	Adequate residual ridge to support an overdenture
	Adequate bone volume to accommodate two implants at least 10 mm in length
	Ability and willingness to maintain oral hygiene
	Need for improved retention and lateral stabilization of tissue-supported denture
Cautions	Flat ridges that would cause loading of implant abutments during function
	Diseases or conditions that could adversely affect implant health and survival
	Poor bone quality that could compromise implant survival
	Implants that diverge more than 28° from each another

prior to pick-up in the denture base. Cap Attachments consist of a retentive nylon liner and a metal housing. When the nylon liners wear out, they can be removed from the metal housings and replaced with new liners without having to relin the overdenture. Guidelines for this type of restoration are summarized in Table 1.

### Direct pick-up technique

After implant placement, osseointegration, and release by the dental surgeon, the patient may be reappointed to begin restorative procedures. The tops of the implants will be visible and located slightly above the soft tissue, and the surrounding gingiva should appear healthy and fully mature. The dental surgeon may have

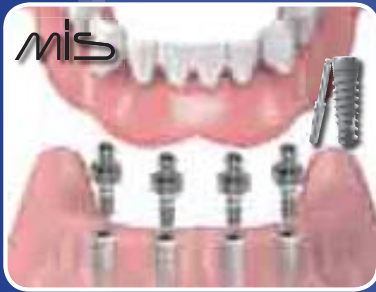relieved the patient's existing denture and placed a soft liner to prevent impingement of the implants during the postoperative healing period. Healing screws (or healing screws with height extenders) will have been placed into the tops of the implants. At this time, the healing screws should be unthreaded and removed with a 1.25 mm-diameter hex tool.

Ball Abutments are one-piece components that consist of a male ball that rises above a 1-mm-high collar, and a threaded shaft that screws directly into the implant [Fig. 1]. For optimum functioning, the top of the Ball Abutment collar should be approximately 1 mm above the highest point of the soft tissue; however, it is important to keep the abutment height as low as possible



**BIODENIX  
TECHNOLOGIES INC**  
ORAL HEALTH FOR LIFE

*The preferred implant solution  
for long term denture stability.*



## TECHNOLOGY



## INSPIRATION



## EDUCATION

*Call today for your free catalogue!*

1.800.313.8338

[www.biodenix.com](http://www.biodenix.com)

in order to decrease the lever-arm effect applied to the implants by the tissue-supported overdenture. When additional height is needed, the 2 mm height extender can be used with the Ball Abutment to obtain 3 mm of vertical height from the top of the implant. The 1.25 mm-diameter hex tool is placed in a properly calibrated torque wrench and used to screw the Ball Abutment into the implant and tighten to 30 Ncm of applied torque [Fig. 2]. The implant portion of the restoration is now complete.

The next step will be to process the Cap Attachments into the base of the patient's existing denture. Alternatively, Cap Attachments can also be easily incorporated into the baseplate of a new denture prior to processing. Cap Attachment Transfers are placed on the Ball Abutments in the patient's mouth, and Cap Attachment Housings are placed over them. Undercuts beneath the Cap Attachment Housings are blocked out with soft utility wax or other material to prevent the ingress of acrylic during the pick-up procedure [Fig. 3].

The base of the patient's existing denture is carefully relieved above the locations of the Cap Attachment Housings [Fig. 4], and care is taken to ensure that the housings fit passively inside the base when the denture is placed in the patient's mouth. Autopolymerizing acrylic is placed into the relieved areas of the denture [Fig. 5], and the prosthesis is carefully positioned in the patient's mouth to pick up the Cap Attachment Housings [Fig. 6]. Adding lingual vents to the relieved areas of the denture is recommended to facilitate the release of excess autopolymerizing acrylic during this step. After the material sets, voids around the housings are filled in with additional autopolymerizing acrylic, and then the tissue-contacting surfaces of the denture are smoothed and polished.

The remaining block-out material and Cap Attachment Transfers are removed from the Ball Abutments in the patient's mouth. One retentive nylon liner is pressed into one of the incorporated Cap Attachment Housings in the denture base [Fig. 7] and its retention is evaluated on the Ball Abutment in the patient's mouth. If necessary, retention can be decreased with the coring tool provided in the set of Cap Attachment Instruments. The same procedures are performed with the second Cap Attachment to complete the restoration [Fig. 8].

## Discussion

The ball-and-socket attachment allows a full range of prosthesis motion and maximum contact between the overdenture and the mucosa during mastication. Placing the retentive sockets in the overdenture base reduces hydraulic resistance to coupling and lowers functional stresses on the implants. For the dentist, the ability to decrease retention to meet specific patient needs, utilize the attachments on implants that are only relatively parallel, and replace retentive Cap Attachment Nylon Liners without the need to relin the denture make the system easy to use and maintain.

Patients can eat a wider range of food items with less difficulty, and experience significantly greater confidence in conversation, social activities and intimacy than conventional denture patients.<sup>3</sup> All of these factors can positively influence patient health and quality of life.

## Conclusions

The implant-retained and -stabilized overdenture represents the first-choice standard of care for patients with edentulous mandibles. Prosthetic procedures and replacement of retentive sockets are relatively simple, and the ability of the patient to remove the overdenture facilitates good oral hygiene.

## References

1. Feine JS, Carlsson GE, Awad MA, et al. The McGill consensus statement on overdentures. Montreal, Quebec, Canada. May 24-25, 2002. *Int J Prosthodont.* 2002;15:413-414.
2. Markiewicz MR, Marincola M, Arévalo Tovar L, Margarone JE III, Garlapo DA, Chuang SK. Building on the proceedings of the McGill Conference: implant-retained overdentures in an area of South America. *Implant Dent.* 2008;17:288-298.
3. Heydecke G, Thomason JM, Lund JP, Fiene JS. The impact of conventional and implant supported prostheses on social and sexual activities in edentulous adults. Results from a randomized trial 2 months after treatment. *J Dent.* 2005;33:649-657.

SPRING/PRINTEMPS 2009

The Journal of Canadian Denturism / Le Journal de la Denturologie Du Canada

# Denturism

DENTUROLOGIE CANADA



In search of a  
**great**  
cast partial

**ALSO:**

- Modification of a conventional denture for use as an implant-retained overdenture
- Legal issues